

Artículo de Revisión

Adult Brachial Plexus Injuries: Treatment in the Acute Phase

Lesiones de Plexo braquial en adultos: tratamiento en la fase aguda

María Cristina Rodríguez-Ricardo¹, Alexander Shin²

¹ Hospital Serena del Mar - Orthopedics department- Hand surgery service- Cartagena - Colombia.

² Mayo Clinic - Division of Hand and Microvascular Surgery - Rochester - United State of America.

Información del artículo

Received: 09/2023

Accepted: 02/2024

Corresponding author: María Cristina Rodríguez. Servicio de Cirugía de Mano, Departamento de ortopedia, Hospital Serena del Mar. Cartagena. Colombia.
Email: mcristina182@gmail.com

Palabras clave: Plexo braquial; Neuropatías del Plexo Braquial; Traumatismos de los Nervios Periféricos.

Keywords: Brachial plexus; Brachial Plexus Neuropathies; Peripheral Nerve Injuries.

DOI: <https://doi.org/10.25214/28056272.1678>

Resumen

Las lesiones del plexo braquial son eventos catastróficos que afectan de diversas formas a los pacientes. Aunque muchas opciones de tratamiento son discutidas en la literatura, se deben aplicar principios generales, especialmente en la fase aguda. Además del conocimiento del cirujano experto sobre la anatomía y las características de la lesión, es imperativo educar al paciente sobre las ramificaciones de su lesión y proporcionar expectativas claras de resultados realistas tanto para el cirujano como para el paciente.

A continuación, se presenta una revisión de los principios del tratamiento quirúrgico agudo de lesiones del plexo braquial.

Abstract

Brachial Plexus Injuries are a catastrophic situation that affects patients on many levels. While many treatment options are discussed in the literature, general treatment principles should be applied, especially in the acute phase. In addition to the expert surgeon's knowledge of the anatomy and characteristics of the injury, it is imperative to educate the patient about the ramifications of their injury and provide clear expectations of realistic outcomes for both the surgeon and the patient. A review of the principles of acute surgical treatment will be presented.

Introduction

Brachial Plexus Injuries (BPI) deeply impact patients' function at many levels. Although the degree of impairment depends on the extent of injury, upper extremity function is permanently altered. BP surgery aims to restore as much function as possible to make the extremity the best helper arm possible. In some cases, surgery can result in very functional recovery, especially in partial injuries; however, normal function is rarely achieved for most patients with complete injuries.

Surgical reconstruction can be divided into acute (within six months from injury) and chronic (greater than one year from injury) phases. Acute reconstruction often focuses on nerve reconstructions (nerve grafting, nerve transfers, acute free-functioning muscle transfers, etc.). In contrast, chronic reconstructions include late free-functioning muscle transfers, tendon transfers, select joint fusions, or amputation with a myoelectric hand. The best functional results are obtained in upper plexus palsies (i.e., C5 and C6 injury), as regaining shoulder and elbow function is particularly useful when the patient has a normal hand. Pan brachial plexus or lower trunk injuries remain challenging to restore function, and functional outcomes after surgery are rarely normal. This review will detail the acute surgical reconstruction options for traumatic adult brachial plexus injuries.

Timing of Surgery

The timing of exploration is based primarily on the mechanism of trauma. Open trauma, blunt or sharp injuries are the primary indication of immediate exploration and repair or nerve grafting. Sharp injuries usually allow for immediate repair. In blunt injuries, the nerve ends should be appropriately tagged and repaired three to four weeks later when the edema has resolved, and the extent of nerve injury can be identified. Brachial plexus exploration should be performed concomitantly when feasible if vascular exploration is indicated.

Low-velocity gunshot wounds are treated as closed injuries, while high-velocity gunshot wounds are often associated with vascular injury, and damage to neighboring tissues often mandates surgery. In this setting, BP exploration should be performed in the same surgery.

In closed injuries, exploration typically occurs between three and six months. This is to enable for the evaluation of potential spontaneous recovery. Some advocate early exploration, which provides for scar-free dissection and early determination of root avulsion, however, this is not generally feasible in severely injured patients.¹ When there is a high suspicion of complete root avulsions with no chance of spontaneous recovery, surgery could be done within three months from injury when possible.

When diagnosis or referral is delayed, primary nerve surgery can be performed between six and nine months. However, delay over 6 months in intervention has been correlated with poorer outcomes.^{2,3}

A general rule is that primary nerve surgery should be performed up to six months from injury, consideration of primary nerve surgery between 7 and 9 months, and no primary nerve surgery after 12 months from injury.⁴

Priorities of Treatment in Pan Brachial Plexus Injuries

There are limited donor nerves in pan BPI to reconstruct all the arm functions. Thus, establishing priorities of function to restore is necessary. The primary goal of reconstruction is elbow flexion followed by shoulder stability and external rotation. Wrist flexion and extension, when possible, are next obtained. Lastly, restoration of elbow extension and rudimentary grasp are considered. When possible, restoring the protective sensibility of the hand should be considered.

Determinants of Treatment

Type of injury

In preganglionic injuries, root avulsion precludes reconstruction with nerve grafts. These patients are candidates for early surgical interventions with nerve transfers. When the injury is postganglionic, roots can be used for grafting to distal targets with or without concomitant nerve transfers (Figure 1). BP exploration is advisable in most cases, as the possibility of finding a viable root adds valuable sources of axons for reconstruction.

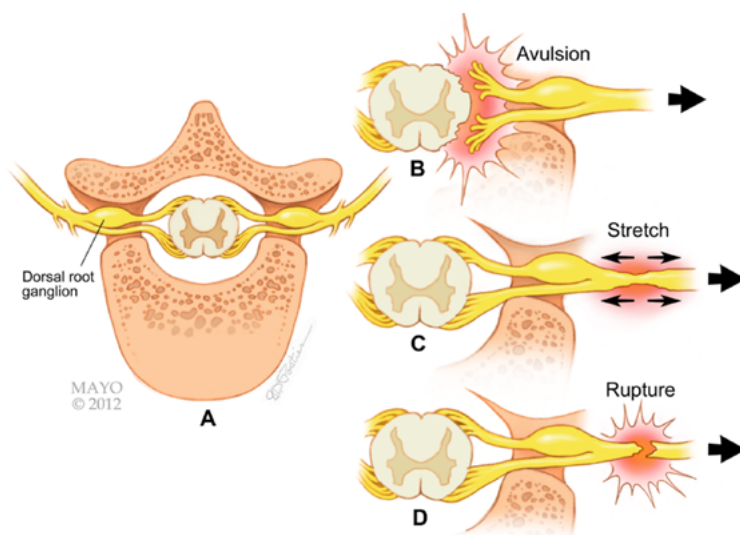


Figure 1. A) Cross sectional diagram of a cervical spine level showing the ventral and dorsal root exiting the vertebral foramen and location of dorsal root ganglion B) Avulsion or preganglionic injury occurs proximal to dorsal root ganglion location. C) Postganglionic injuries are located distal to the dorsal root ganglion. D) Stretch injuries can also occur.

Source: Used with permission of Mayo Foundation for Medical Education and Research. All rights reserved.

Patterns of injury

With five roots, multiple rootlets, and many locations where the plexus can be injured, the number of permutations of injury types is nearly infinite (Figure 2). Pattern based on plexus region has been described as upper, lower, and pan plexus injuries. Upper trunk palsies involve C5 and C6 roots, generally have better outcomes, as numerous nerve donors for transfer and possible viable root(s) are available for grafting.



Figure 2. Roots may be damaged at different levels and combination of roots compromised determine treatment. Preganglionic C5-C6-C7 injury and Postganglionic C8-T1 injury is shown, accounting for a complete Brachial plexus injury. Source: Used with permission of Mayo Foundation for Medical Education and Research. All rights reserved.

In lower trunk injuries, distance from the injury site to the target muscle makes root grafting impractical and impossible. Surgical treatment aims to restore extrinsic muscle function, while intrinsic hand muscles cannot be restored.

Pan plexus injuries involve all roots and often combine pre and post ganglionic injuries. A five-level avulsion limits reconstruction to extraplexal nerves such as intercostals (IC) or spinal accessory nerves (SAN) for nerve transfer only. Controversial extraplexal nerve sources include the ipsilateral phrenic nerve, hypoglossal and contralateral C7. In pan plexus injuries, hand function rarely improves with nerve transfer/grafting techniques, and acute application of a free-functioning muscle may provide a rudimentary grasp.

Secondary surgeries, such as wrist and thumb axis fusion, are often needed to optimize the rudimentary grasp.

Concomitant injuries

Due to concomitant life-threatening injuries, approximately 5 to 15% of vascular injury diagnoses are delayed.⁵ When BP injury and clavicle fracture coexist, injury to the axillary and subclavian artery is fifty times higher.⁶ Around 30% of patients present with head trauma, 38% with long bone fractures, and 12% with thoracic trauma.⁷ Life-threatening conditions must be managed, and fractures should be stabilized before addressing brachial plexus injuries.

Surgical Options in the Acute Setting

Nerve Grafting

Advocates of nerve transfer often forgo brachial plexus exploration and grafting citing easier surgery, earlier regeneration, and better results

obtained from nerve transfers. Some authors even advocate for abandoning BP exploration completely, especially in upper palsies.⁸

Despite this, it is imperative to understand that BP exploration has significant benefits: it provides an understanding of the injury pathoanatomy and nerve grafting of viable roots allows regeneration of axons down the native pathway reinnervating multiple muscles and restoring sensation. Roots provide a far greater number of axons than any extra plexal source and using all available, viable nerve roots allows for sparing of extraplexal donors which may be useful in future FFMT (Free Functioning muscle Transfer) or tendon transfers (i.e., lower trapezius for external shoulder rotation). It is essential to keep in mind that nerve transfers do not restore brachial plexus native anatomy; in all cases of nerve transfer, there is some function that needs to be sacrificed for a single muscle to be reinnervated. There are specific prerequisites for root grafting: motor end plates in target muscles must be viable at the time of expected reinnervation (i.e., time from injury less than six to eight months), and enough donor nerve graft must be available. A root is considered eligible for grafting when it is in continuity to the spinal cord. Ideally, intraoperative SSEP/MEP (Somatosensory evoked potentials / Motor evoked potentials) are recommended to ensure the viability of the root, even if histology or physical evaluation demonstrated viable motor axons.⁹

As direct coaptation of the root stump to the distal ruptured nerve is not feasible secondary to scar formation, interposition cable grafting with autologous nerve grafts is required. C5 root to the posterior division of the Upper Trunk (PDUT) and Suprascapular nerve (SSN) (shoulder reconstruction) (Figure 3), and C6 root to the Anterior Division of the Upper Trunk (ADUT) (elbow flexion) is a common option.^{10,11}

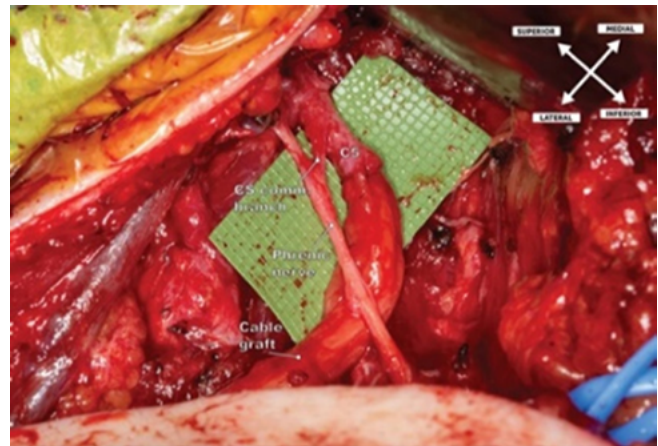


Figure 3. Surgical photograph showing brachial plexus supraclavicular approach and nerve cable graft from C5 root to Suprascapular nerve and Posterior Division of the Upper Trunk targeting Axillary Nerve for shoulder reanimation. The root of C5 is in continuity with the spinal cord and Phrenic nerve is shown with its C5 contribution.

Source: Take from Noland *et al.*¹¹; used with permission of Mayo Foundation for Medical Education and Research, all rights reserved.

When multiple roots are available, the limiting factor is the availability of autologous donor nerve grafts. Grafts are obtained from bilateral sural nerves or ipsilateral superficial branch of radial nerve in pan plexus injuries.

Nerve Transfers

This technique transfers a healthy nerve of lesser functional importance to a more important injured nerve. They are indicated when axonal regrowth will not reach the paralyzed muscle before the motor endplates become nonfunctional, secondary to the distance to target muscle. Nerve transfers may be intra or extra plexal according to the donor's origin.

General principles must be considered:

1. Redundancy of donor nerve: an ideal donor is expendable; its absence does not result in a functional loss. The best example is transferring an ulnar nerve fascicle to the Flexor Carpi Ulnaris (FCU) muscle to the biceps motor branch.
2. Agonistic function of donor's nerve: Re-education after the transfer is easier when muscles innervated by the donor's nerve serve a similar function to the recipient's muscle.
3. Distal transfer to the donor nerve: the closer to the paralyzed muscle, the faster it will be reinnervated.

4. One transfer - One function: a transferred nerve should be directed to a motor nerve of a specific muscle to optimize results.
5. Matching diameter: The number of motor axons transferred is vital for functional recovery.

In Upper plexus injuries (C5-C6), potential donor nerves include medial or long head of triceps, ulnar nerve fascicle to the FCU and SAN. In C7 - C8 - T1 injuries, motor branches for Brachialis muscle from the musculocutaneous nerve (MCN) are available and the motor branch to the supinator muscle, innervated by C6, is also useful for a potential Supinator to posterior interosseous nerve (SPIN) transfer. Other intra-plexal nerve donors include the lateral pectoral, thoracodorsal, and anterior interosseous nerve, depending on the injury pattern.

It is common to use nerves external to the brachial plexus for transfer, not only because of lack of donors as in pan BPI, but also because of the vicinity of the donor nerves. The most common donor nerves in pan BPI are SAN and IC nerves (Figure 4). Phrenic nerve is also available, but caution must be exercised in its use, especially for patients with high BMI or low respiratory reserve.

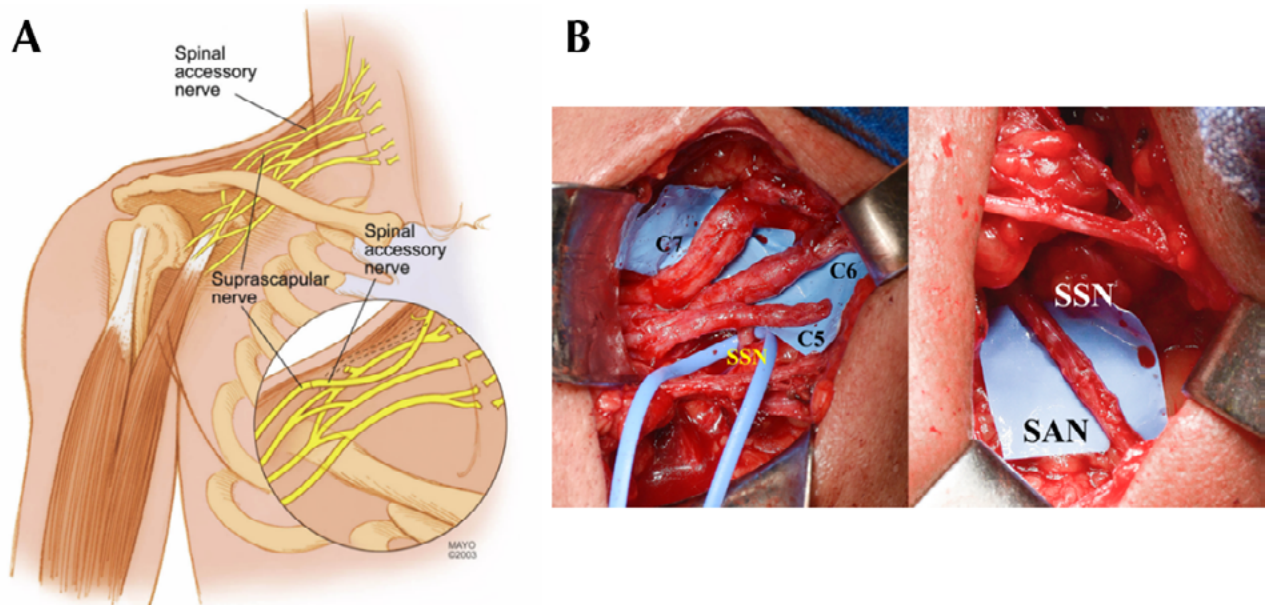


Figure 4. A). Diagram of a pan plexus injury, Spinal Accessory nerve (SAN) and its close anatomic relation to the brachial plexus can be seen. In a closeup SAN to Suprascapular nerve Transfer is shown. B) Intraoperative photo of a preganglionic C5-C6 injury; the image on the left shows the location of the Suprascapular nerve emerging the C5 avulsed root. The image on the right shows the spinal accessory nerve transferred to the suprascapular by a tensionless direct coaptation.

Source: Used with permission of Mayo Foundation for Medical Education and Research. All rights reserved.

While the contralateral Hemi C7 transfer is a source of many axons, it does not comply with the principles of synergistic function. Its use remains controversial.¹²⁻¹⁴ Adult patients typically required the contralateral extremity to activate the function on the injured side and all found the lack of independence impractical.¹³

Free Functioning Muscle Transfers

Gracilis free functioning muscle transfer (FFMT) is a reconstruction technique that may be used to restore elbow flexion or extension, with or without wrist extension and potential grasp (Figure

- 5). In the acute patient, it is especially useful for total palsies where donors are limited and if hand function is within the reconstruction goals, the absence of vascular injury and a complete microsurgery team are required.

The most common nerve donors include the SAN and IC. While no statistical difference exists in the outcome, there is convincing evidence that control is improved with SAN compared to ICN. Two versus three or four IC motor nerves make no difference in results either.

Gracilis FFMT has the advantage of faster reinnervation due to its proximal pedicle, which leads to a shorter distance between the nerve donor and the motor end plate (Figure 6).

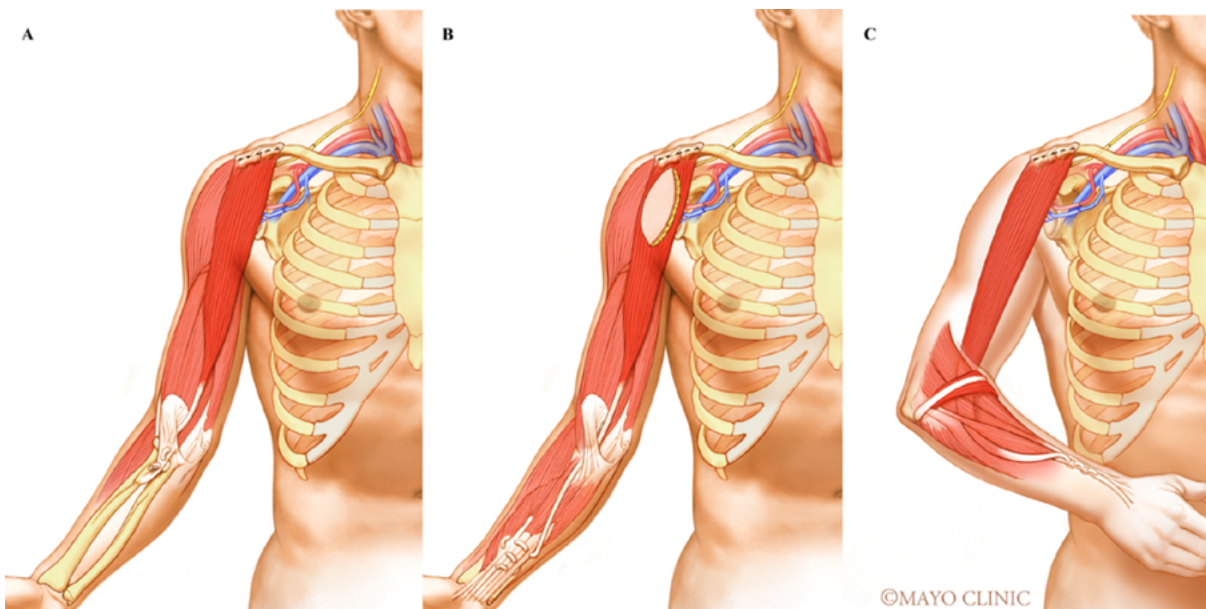


Figure 5. Diagram of Functional Gracilis Transfer, neurotized with accessory spinal nerve, vascular anastomosis to the thoraco-acromial trunk and proximal bone fixation to the clavicle. Alternatives of distal fixation in Gracilis Transfer are exemplified: to approach only elbow flexion it is attached to the biceps tendon (A), for grasp and elbow flexion it is passed under the biceps tendon and attached to the finger flexor tendons (B) For elbow flexion and wrist extension it is passed under the biceps tendon, around wrist extensor muscles and attached to radial wrist extensor tendons (C).

Source: Used with permission of Mayo Foundation for Medical Education and Research. All rights reserved.

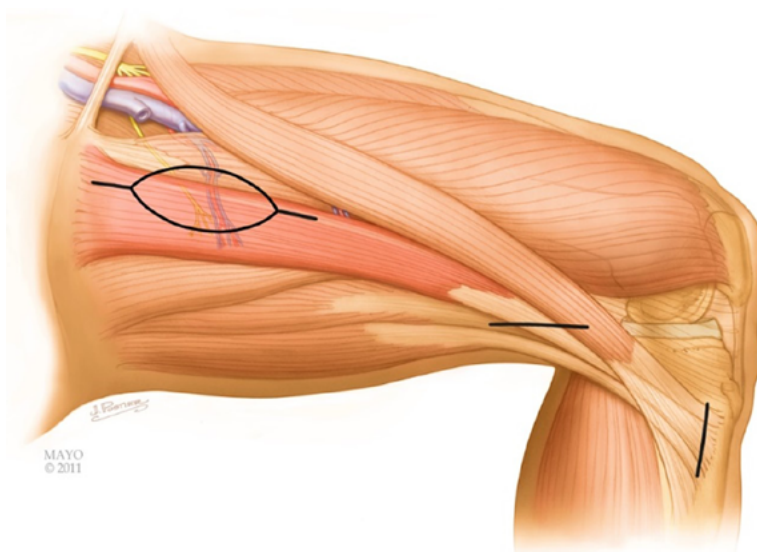


Figure 6. Diagram showing Gracilis Harvest which may be done through 3 separate incisions: a 4cm incision in the medial distal thigh and at the pes anserinus, allow releasing the distal tendon from soft tissue attachments. A proximal elliptical incision anterior to the anterior border of the gracilis centered about the skin perforators in the medial proximal third of the thigh, allows dissection of the neurovascular pedicle comfortably. The dominant arterial supply is provided by a branch from the profunda femoris artery 8 to 12 cm from the muscular origin at the pubic symphysis, motor innervation is provided by a branch of the obturator nerve.

Source: Used with permission of Mayo Foundation for Medical Education and Research. All rights reserved.

It offers the possibility of being performed at any time after the injury and it makes restoration of basic hand function possible in the acute phase. Triceps reinnervation is needed to oppose elbow flexion associated with

the grasp, at least M2 power of elbow extension is necessary to act as agonist elbow flexion during finger movement.¹⁵ Therefore, it should be considered in acute injuries that involve the whole brachial plexus.

Acute Options Based on Injury Pattern

C5-C6

Options vary according to root availability for 6 months or less, as shown in Figure 7.

C5-7

In this injury pattern, the priorities of treatment need to be considered (Figure 8).

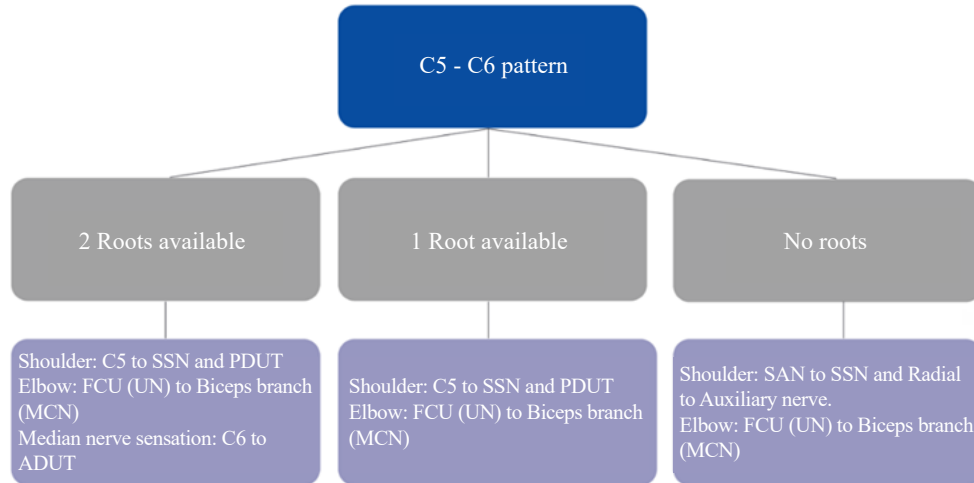


Figure 7. Algorithm of Acute Options for C5-C6 Injury pattern according to root availability at brachial plexus exploration. SSN: Suprascapular Nerve; PDUT: posterior division of upper trunk; FCU: Flexor carpi ulnaris; UN: Ulnar nerve; MCN: Musculocutaneous Nerve; ADUT: anterior division of upper trunk; SAN: Spinal Accessory Nerve; LHTB: Long head of triceps branch. Source: Own elaboration.

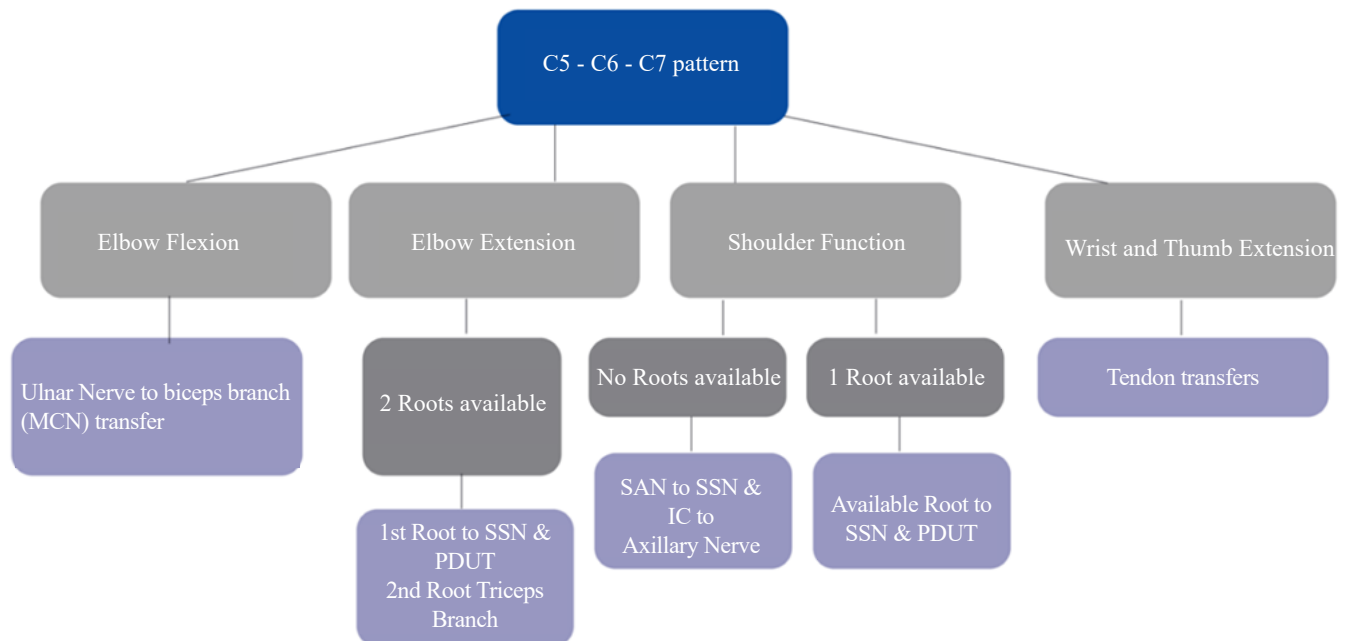


Figure 8. Algorithm of Acute Options for C5-C7 Injury pattern according to intended function reconstruction. A combination of techniques are listed for shoulder function and elbow extension depending on root availability for grafting. MCN: Musculocutaneous Nerve; SAN: Spinal Accessory Nerve; SSN: Suprascapular Nerve; IC: Intercostals; PDUT: Posterior Division Upper Trunk. Source: Own elaboration.

Pan plexus (with 1-3 root available, and none) within 6 months of injury

In this setting there are multiple options. It is important to list the options as well as all potential permutations. While this is an exhaustive exercise, it is invaluable in understanding the options. In all cases surgeon preference, microsurgical team availability, patient's expectations and financial resources need to be considered.

One Root available

This is a very common scenario and has several options for reconstruction as illustrated in Figure 9.

Two Roots available

This scenario is uncommon and options are detailed in Figure 10.

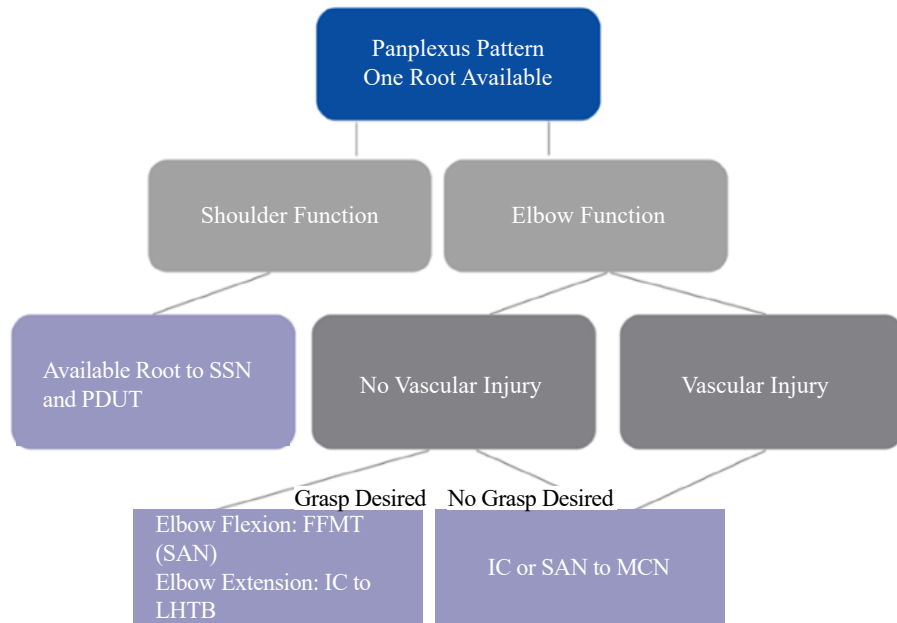


Figure 9. Acute Options for Pan Plexus Injury pattern with One root available. Available root is used for shoulder reanimation and different option for elbow flexion are shown depending on presence of vascular injury and intention to recover grasp. FFMT: Free functioning muscle transfer; SAN: Spinal Accessory nerve; IC: Intercostals; LHTB: Long head of triceps branch; MCN: Musculo-cutaneous Nerve.

Source: Own elaboration.

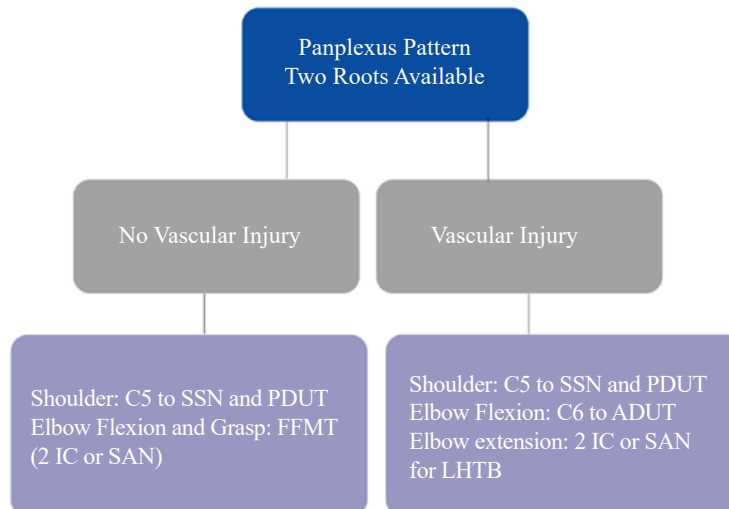


Figure 10. Acute Options for Pan Plexus Injury pattern with Two roots available. Vascular injury precludes use of Gracilis Transfer. SSN: Suprascapular Nerve; PDUT: posterior division of upper trunk; FFMT: Free functioning muscle transfer; IC: Intercostals; SAN: Spinal Accessory nerve; ADUT: Anterior division of Upper trunk; LHTB: Long head of triceps branch.

Source: Own elaboration.

No Roots available

This is the most common scenario in our experience. A balanced decision-making process accounting for the patient's goals,

the surgeon's experience, and realistic expectations are made (Figure 11).

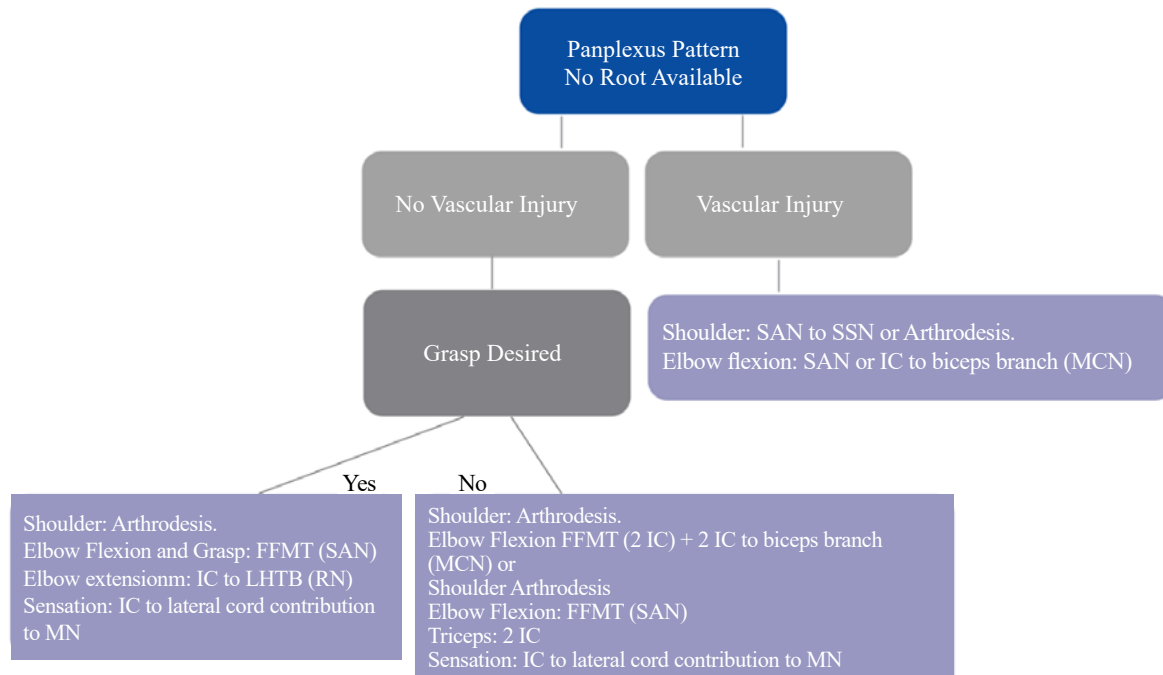


Figure 11. Acute Options for Pan Plexus Injury pattern without available roots. Availability of nerve donors is the main restrictive factor when a vascular injury is present only shoulder and elbow function are amenable of reconstruction. In this setting Free functioning muscle transfer becomes When there is possibility of a Gracilis transfer, options are listed for elbow, shoulder function and grasp. FFMT: Free functioning muscle transfer; SAN: Spinal Accessory nerve; IC: Intercostals; LHTB: Long head of triceps branch; RN: Radial nerve; MN: Median nerve; MCN: Musculocutaneous nerve; SSN: Suprascapular Nerve.

Source: Own elaboration.

Postoperative Management

Patients are immobilized in a sling for three weeks to allow nerve coaptations to heal and an additional three weeks to allow the FFMT tendon sites to heal. Passive motion is started at six weeks. Electrostimulation has not proven effective in humans, and as such, we do not use it. Follow-up is advised every six to eight months over a five-year period to assess recovery and perform secondary procedures when indicated. The patient should ideally be followed for up to 5 years.

Anticipated Outcomes

Nerve Grafting

Upper trunk Injuries that are amenable for reconstruction with combination of intraplexal root grafting and nerve transfers, show better outcomes in strength compared to nerve transfers alone.¹⁶ When nerve transfers and nerve grafting are compared in isolation, functional outcomes of nerve transfers for elbow flexion are only statistically superior for C5-C6 pattern injuries (93% vs. 69% of M3 or higher).

In C5-C6-C7 patterns and total palsies, there is no difference between grafting and nerve transfers regarding function.¹⁷ The currently available data regarding shoulder outcomes remain inconclusive; therefore, nerve grafting should remain an option in postganglionic 3 to 6 months injuries.

Nerve Transfers

Outcomes of more common nerve transfers are reviewed.

SAN to SSN and/or Radial to Axillary nerve (AN) (Figure 12), provide an average shoulder abduction range of motion of 92° with M3 and M4 or higher strength recovery in around 80% and 40%, respectively. Dual nerve transfers and direct coaptation transfers result in better shoulder abduction strength and range of motion.¹⁸

Ulnar nerve fascicle to biceps motor branch first described by Oberlin *et al.*¹⁹ (Figure 13) has reported success rates above 90% when performed within 6 months from injury (MRC>3), without ulnar nerve disfunction.²⁰ However, recovery of M4 and M5 has been reported on patients with over one year of injury, thus it may be attempted in patients after 12 to 24 months from injury, because risk benefit ratio is still favorable.^{21,22}

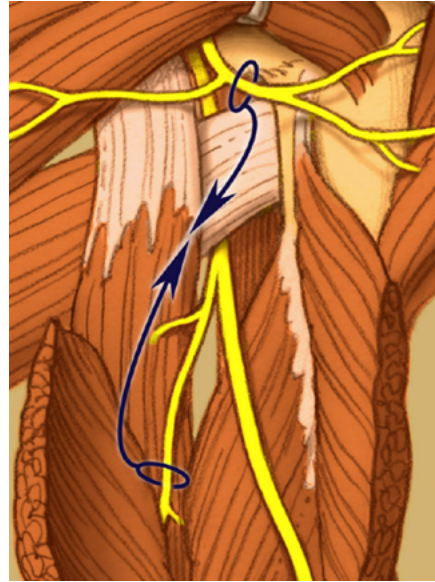


Figure 12. Diagram of posterior shoulder wall, Axillary nerve emerging from anterior to posterior through the quadrangular space above the Teres major and Radial nerve through triangular interval below Teres major. Long head of triceps muscle is the medial limit of these spaces. LHTB to Axillary nerve transfer as described by Leechavangvongs *et al.* may be done by a posterior or axillar approach. Source: Used with permission of Mayo Foundation for Medical Education and Research. All rights reserved.

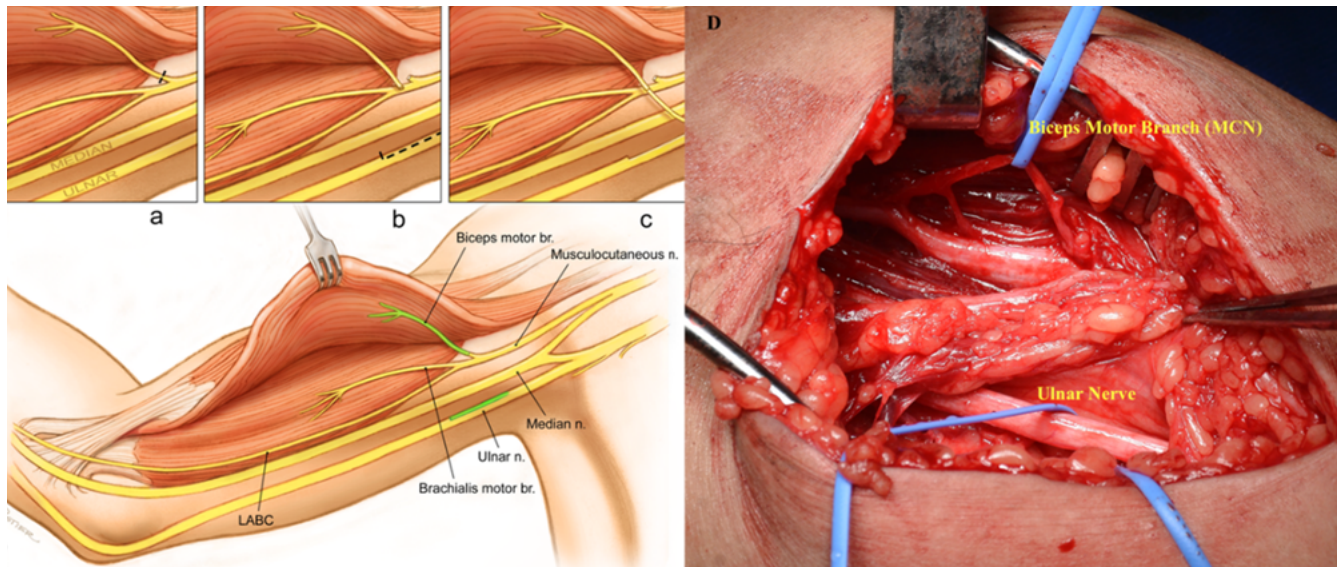


Figure 13. Diagram of Ulnar nerve transfer to biceps motor branch step by step. Biceps motor branch and motor branch of FCU are shown in green. A) Closeup view of the anatomy of motor branches of musculocutaneous nerve entering Biceps and Brachialis muscles. B) Biceps motor branch is sectioned before entering the muscle and Flexor carpi ulnaris motor branch is harvested from Ulnar nerve by intraneural dissection. C) Transfer is completed by direct coaptation. D) Intraoperative view showing corresponding anatomy from diagram. Forceps show Median Nerve. Source: Used with permission of Mayo Foundation for Medical Education and Research. All rights reserved.

When successful, range of elbow flexion are comparable between patients with ICN and Oberlin transfers, however in the latter, a stronger concentric contraction is achieved probably because of simultaneous activation of forearm muscles.^{23,24}

Regarding C5-C7 injuries, PQ motor branch to the ECRB reported M4-level strength in over 90% of patients.^{25,26}

Free Functioning Muscle Transfer

Grade M4 elbow flexion strength is obtained in 79% of the FFMTs for elbow flexion alone (single transfer) and 63% when transferred for combined motion.²⁷

Compared to ICN to biceps nerve transfer performed within 5,4 months from injury, FFMT yielded statistically better results in a cohort of 62 patients in terms of functional strength recovery (41.9% vs. 67.7% of M3/M4 elbow flexion).²⁸ Whereas ICN transfer for elbow flexion results are inconsistent in the literature, 0 to 78% of M4 elbow flexion recovery has been reported, which makes it difficult to discuss with patients.

Role of amputation and Myoelectric Prosthesis for Grasp

In the seventies, transhumeral amputation, shoulder arthrodesis and prosthetic fitting was first line treatment for patients with preganglionic brachial plexus injuries.²⁹ Nerve surgery has changed BP injury treatment and prognosis, relegating amputation for failures.³⁰

Persistent mechanical shoulder pain, failure to restore limb function and complications are common reasons for patient to ask for an amputation. If pain is caused by the weight of a flail arm or glenohumeral subluxation, shoulder fusion and amputation (level according to necessity) is beneficial with evidence demonstrating improvement in DASH and VAS scores.^{31,32} Patients should be informed that neuropathic pain due to preganglionic injuries, does not improve with amputation.

Amputation and prosthetic fitting still have a role in brachial plexus injuries among patients that undergo unsuccessful reconstructive surgeries, usually 24 months after the last reconstructive attempt. High rates of patient satisfaction are obtained when there is a proper indication and sufficient patient education.^{31,33} Transradial amputation and fitting of myoelectric prosthesis increases its use in daily activities three times more compared to proximal amputation and use of traditional prosthesis.³²

Advances in prosthetic engineering with availability of light-weight modern myoelectric prosthesis, bring other factors to the discussion. The chance of recovering or enhancing manual function that otherwise may not be gained by nerve surgery is something to consider, more than merely the benefit of losing the flail limb but the opportunity to have active hand control.

Management of Pain

Pain is a major factor in 70% of BPI patients, 95% is neuropathic secondary to the injury caused at the spinal cord level although it may appear in postganglionic injuries because of neuroma formation or compression due to scarring.^{34,35} Phantom limb sensation is present in 40% of patients.³⁶

Pharmacologic treatment is first line of management with central nervous system acting drugs such as Tricyclic antidepressants (amitriptyline, nortriptyline) and calcium channel ligands (gabapentin, pregabalin). Opioids (tramadol, oxycodone, methadone), Anticonvulsants (carbamazepine, clonazepam), other antidepressants (venlafaxine, duloxetine) and neuroleptic drugs may be effective but reserved for second-line treatment.

Physical therapy, acupuncture, cannabis and low intensity TENS (transcutaneous electrical nerve stimulation) work in some patients.³⁷ Peripheral spinal cord and brain stimulation for pain signaling modulation, and Dorsal root entry zone (DREZ) lesioning, intended to stop dorsal horn ascending pathway, are therapies used for refractory neuropathic pain. DREZ is effective in 70 to 90% of patients, pain tends to recur after 5 years in around 20% but less intense, amenable for treating with pharmacologic agents.³⁸

Conclusions

Treatment of Brachial plexus injuries is dependent on multiple factors. Time elapsed and physical findings at the presentation guide, number of roots involved and concomitant injuries affect treatment options. The specific surgical plan is adjusted according to patient's deficit, goals of reconstruction, availability of nerve donors, and expertise of the treating surgeon.

Surgical options include nerve root grafting, intraplexal and extraplexal nerve transfers and Free functioning muscle transfers. Different combinations are plausible, but every case is unique. Although nerve transfers have become popular lately, exploration of brachial plexus is key because available roots are an invaluable source of axons for motor and some sensibility recovery, they could also spare the use of nerve donors that may allow restoration of more limb function and may aid in pain management, as well.

Advances in prosthetic engineering and availability of modern myoelectric devices, give patients an opportunity to regain elbow and hand control as part of their treatment algorithm. Brachial plexus injuries remain a catastrophic event, however, as surgical techniques develop, more alternatives arise and better outcomes on limb function can be offered to patients imparting a positive impact on their quality of life.

Conflicts of interest

None stated by the authors.

Funding

None stated by the authors.

Acknowledgments

None stated by the authors.

References

1. Groen JL, Pondaag W, Malessy MJA. Early grafting in severe adult traumatic brachial plexus injury. *Neurosurg Focus Video*. 2023;8(1):V13. DOI: 10.3171/2022.10.FOCVID2288.
2. El-Gammal TA, Fathi NA. Outcomes of surgical treatment of brachial plexus injuries using nerve grafting and nerve transfers. *J Reconstr Microsurg*. 2002;18(1):7-15. DOI: 10.1055/s-2002-19703.
3. Bertelli JA, Ghizoni MF. **Results** and current approach for Brachial Plexus reconstruction. *J Brachial Plex Peripher Nerve Inj*. 2011;6(1):2-8. DOI: 10.1186/1749-7221-6-2.
4. Socolovsky M, Di Masi G, Battaglia D. Use of long autologous nerve grafts in brachial plexus reconstruction: Factors that affect the outcome. *Acta Neurochir (Wien)*. 2011;153(11):2231-40. DOI: 10.1007/s00701-011-1131-1.
5. Rodríguez-Ricardo MC, García-González LA, Shin AY. Adult Brachial Plexus Injuries. Part 1: Anatomy, Exam and Evaluation. *Cirugía Mano y Microcirugía*. 2021;1(1):15-23. DOI: 10.25214/28056272.1177.
6. Tay E, Grigorian A, Schubl SD, Lekawa M, de Virgilio C, Scolaro J, *et al*. Brachial Plexus Injury Significantly Increases Risk of Axillosubclavian Vessel Injury in Blunt Trauma Patients

- With Clavicle Fractures. *Am Surg.* 2021;87(5):747-52. DOI: 10.1177/0003134820952832.
7. Faglioni W, Siqueira MG, Martins RS, Heise CO, Foroni L. The epidemiology of adult traumatic brachial plexus lesions in a large metropolis. *Acta Neurochir (Wien).* 2014;156(5):1025-8. DOI: 10.1007/s00701-013-1948-x.
 8. Yang LJS, Chang KWC, Chung KC. A systematic review of nerve transfer and nerve repair for the treatment of adult upper brachial plexus injury. *Neurosurgery.* 2012;71(2):417-29. DOI: 10.1227/NEU.0b013e318257be98.
 9. Zelenski NA, Oishi T, Shin AY. Indications and Technique for the Use of Intraoperative Neuromonitoring in Brachial Plexus Surgery. *J Hand Surg Am.* 2023;48(7):726-31. DOI: 10.1016/j.jhsa.2023.01.019.
 10. Gillis JA, Khouri JS, Kircher MF, Spinner RJ, Bishop AT, Shin AY. Outcomes of elbow flexion reconstruction in patients older than 50 with traumatic brachial plexus injury. *Plast Reconstr Surg.* 2019;143(1):151-8. DOI: 10.1097/PRS.0000000000005094.
 11. Noland SS, Bishop AT, Spinner RJ, Shin AY. Adult Traumatic Brachial Plexus Injuries. *J Am Acad Orthop Surg.* 2019;27(19):705-16. DOI: 10.5435/JAAOS-D-18-00433.
 12. Li S, Cao Y, Zhang Y, Jiang J, Gu Y, Xu L. Contralateral C7 transfer via both ulnar nerve and medial antebrachial cutaneous nerve to repair total brachial plexus avulsion: a preliminary report. *Br J Neurosurg.* 2019;33(6):648-54. DOI: 10.1080/02688697.2019.1675866.
 13. Sammer DM, Kircher MF, Bishop AT, Spinner RJ, Shin AY. Hemi-Contralateral C7 Transfer in Traumatic Brachial Plexus Injuries: Outcomes and Complications. *J Bone Joint Surg Am.* 2012;94(2):131-7. DOI: 10.2106/JBJS.J.01075.
 14. Zou YW, Wang ZJ, Yu H. Treatment of brachial plexus injury with modified contralateral C7 transfer. *Orthop Surg.* 2010;2(1):14-8. DOI: 10.1111/j.1757-7861.2009.00057.x.
 15. Dodakundi C, Doi K, Hattori Y, Sakamoto S, Fujihara Y, Takagi T, *et al.* Outcome of surgical reconstruction after traumatic total brachial plexus palsy. *J Bone Joint Surg Am.* 2013;95(16):1505-12. DOI: 10.2106/JBJS.K.01279.
 16. Bertelli JA, Ghizoni MF. Nerve Root Grafting and Distal Nerve Transfers for C5-C6 Brachial Plexus Injuries. *J Hand Surg Am.* 2010;35(5):769-75. DOI: 10.1016/j.jhsa.2010.01.004.
 17. Ayhan E, Soldado F, Fontecha CG, Bertelli JA, Leblebicioglu G. Elbow flexion reconstruction with nerve transfer or grafting in patients with brachial plexus injuries: A systematic review and comparison study. *Microsurgery.* 2020;40(1):79-86. DOI: 10.1002/micr.30440.
 18. Garg R, Merrell GA, Hillstrom HJ, Wolfe SW. Comparison of nerve transfers and nerve grafting for traumatic upper plexus palsy: A systematic review and analysis. *J Bone Joint Surg Am.* 2011;93(9):819-29. DOI: 10.2106/JBJS.I.01602.
 19. Oberlin C, Beal D, Leechavengvongs S, Salon A, Dauge MC, Sarcy JJ. Nerve Transfer to Biceps Muscle Using a Part of Ulnar Nerve for C5-C6 Avulsion of the Brachial Plexus : Anatomical Study and Report of Four Cases. *J Hand Surg Am.* 1994;19(2):232-7. DOI: 10.1016/0363-5023(94)90011-6.
 20. Leechavengvongs S, Witoonchart K, Uerpairojkit C, Thuvassethakul P, Ketmalasiri W. Nerve transfer to biceps muscle using a part of the ulnar nerve in brachial plexus injury (upper arm type): A report of 32 cases. *J Hand Surg Am.* 1998;23(4):711-6. DOI: 10.1016/S0363-5023(98)80059-2.
 21. Sedain G, Sharma MS, Sharma BS, Mahapatra AK. Outcome after delayed oberlin transfer in brachial plexus injury. *Neurosurgery.* 2011;69(4):822-7. DOI: 10.1227/NEU.0b013e31822848eb.
 22. Verdins K, Kapickis M. Oberlin's Transfer: Long Term Outcomes. *J Hand Surg Asian Pac Vol.* 2018;23(2):176-80. DOI: 10.1142/S2424835518500170.
 23. Chia DSY, Doi K, Hattori Y, Sakamoto S. Elbow flexion strength and contractile activity after partial ulnar nerve or intercostal nerve transfers for brachial plexus injuries. *J Hand Surg Eur Vol.* 2020;45(8):818-26. DOI: 10.1177/1753193420922184.
 24. Emamhadi M, Behzadnia H, Zamanidouost M, Baghi I, Ebrahimi-an R, Emamhadi R, *et al.* Intercostal or ulnar nerve: Which donor nerve is to be used for reanimation of elbow flexion? *Musculoskelet Surg.* 2021;105(2):183-8. DOI: 10.1007/s12306-020-00653-z.
 25. Bertelli JA, Ghizoni MF, Tacca CP. **Results** of wrist extension reconstruction in C5-8 brachial plexus palsy by transferring the pronator quadratus motor branch to the extensor carpi radialis brevis muscle. *J Neurosurg.* 2016;124(5):1442-9. DOI: 10.3171/2015.3.JNS142428.
 26. Bhatia A, Salama M. Pronator Quadratus to Extensor Carpi Radialis Brevis Nerve Transfer in C5-C7 or C5-C8 Brachial Plexus Injuries for Independent Wrist Extension. *Indian J Plast Surg.* 2020;53(1):36-41. DOI: 10.1055/s-0040-1708114.
 27. Barrie KA, Steinmann SP, Shin AY, Spinner RJ, Bishop AT. Gracilis free muscle transfer for restoration of function after complete brachial plexus avulsion. *Neurosurg Focus.* 2004;16(5):E8. DOI: 10.3171/foc.2004.16.5.9.
 28. Maldonado AA, Kircher MF, Spinner RJ, Bishop AT, Shin AY. Free Functioning Gracilis Muscle Transfer versus Intercostal Nerve Transfer to Musculocutaneous Nerve for Restoration of Elbow Flexion after Traumatic Adult Brachial Pan-Plexus Injury. *Plast Reconstr Surg.* 2016;138(3):483e-488e. DOI: 10.1097/PRS.0000000000002471.
 29. Parry CB. The Managment of Brachial Plexus. *Proc R Soc Med.* 1974;67(6 Pt 1):488-90.
 30. Terzis JK, Vekris MD, Soucacos PN. Brachial plexus root avulsions. *World J Surg.* 2001;25(8):1049-61. DOI: 10.1007/s00268-001-0058-8.
 31. Maldonado AA, Kircher MF, Spinner RJ, Bishop AT, Shin AY. The role of elective amputation in patients with traumatic brachial plexus injury. *J Plast Reconstr Aesthetic Surg.* 2016;69(3):311-7. DOI: 10.1016/j.bjps.2015.10.019.
 32. Cantwell SR, Nelson AW, Sampson BP, Spinner RJ, Bishop AT, Pulos N, *et al.* The Role of Amputation and Myoelectric Prosthetic Fitting in Patients with Traumatic Brachial Plexus Injuries. *J Bone Joint Surg Am.* 2022;104(16):1475-82. DOI: 10.2106/JBJS.21.01261.
 33. Robinson LR, Mayo A. When to consider amputation post severe brachial plexus injury. *Can J Neurol Sci.* 2024; 51(1):140-142. doi: 10.1017/cjn.2023.7.
 34. Teixeira MJ, da Paz MG, Bina MT, Santos SN, Raicher I, Galhardoni R, *et al.* Neuropathic pain after brachial plexus avulsion - central and peripheral mechanisms. *BMC Neurol.* 2015;15:73. DOI: 10.1186/s12883-015-0329-x.
 35. Ciaramitaro P, Mondelli M, Logullo F, Grimaldi S, Battiston B, Sard A, *et al.* Traumatic peripheral nerve injuries: Epidemiological findings, neuropathic pain and quality of life in 158 patients. *J Peripher Nerv Syst.* 2010;15(2):120-7. DOI: 10.1111/j.1529-8027.2010.00260.x.

36. Zheng Z, Hu Y, Tao W, Zhang X, Li Y. Dorsal root entry zone lesions for phantom limb pain with brachial plexus avulsion: A study of pain and phantom limb sensation. *Stereotact Funct Neurosurg.* 2009;87(4):249-55. DOI: 10.1159/000225978.
37. Mathews M. Multimodal treatment of pain. *Neurosurg Clin N Am.* 2014;25(4):803-8. DOI: 10.1016/j.nec.2014.07.005.
38. Ruiz-Juretschke F, García-Salazar F, García-Leal R, Fernández-Carballal C, Iza B, Garbizu JM, *et al.* Tratamiento del dolor neuropático por desaferentización mediante lesión DREZ, resultados a largo plazo. *Neurología.* 2011;26(1):26-31. DOI: 10.1016/j.nrl.2010.10.003.