

Original article

Double Dorsal Capsulodesis in the Treatment of Chronic Scapholunate Instability: Description of a New Surgical Technique and Case Report

Doble capsulodesis dorsal en el tratamiento de la inestabilidad escafolunar crónica: descripción de una nueva técnica quirúrgica y presentación de un caso

Niceas da Silva Gusmão Filho¹, Ricardo Kaempf de Oliveira², Givaldo Trindade Rios¹,
Gudson Gleyton Queirós de Sousa³

¹ Hospital Memorial Arthur Ramos, Hand Surgery Department, Maceió, Brazil.

² Santa Casa de Misericórdia de Porto Alegre, Hand Surgery Department, Porto Alegre, Brazil.

³ Move Rehabilitation Center, Hand Therapy Department, Maceió, Brazil.

Correspondence: Niceas da Silva Gusmão Filho. Hand Surgery Department, Hospital Memorial Arthur Ramos, Maceió, Brazil. Email: niceasgfilho@gmail.com.

Article Information Abstract

Received: 15/02/2022

Accepted: 16/04/2022

Keywords: Wrist Injuries; Wrist Joint;
Intercarpal Joints.

Palabras clave: Muñeca, Traumatismos de la
Muñeca, Huesos del carpo.

DOI: <https://doi.org/10.25214/28056272.1486>

Introduction: The scapholunate ligament (SLL) injury can cause wrist pain and instability. There is a wide variety of surgical techniques used for the treatment of this lesion, such as dorsal capsulodeses, tenodeses with flexor or extensor tendons, and bone-ligament-bone graft.

Objective: To describe a new technique for the treatment of SLL injury aiming to stabilize the dissociated carpus with a double dorsal capsulodesis.

Materials and methods: By presenting the case of a 36-year-old male security officer who injured his left wrist in a motorcycle accident, a procedure to align the carpus is proposed. The long-term outcome of this procedure is also described

Results: The proposed surgery was successfully performed; it had excellent clinical and functional results, with no complications. Long-term restoration of carpal alignment observed in wrist radiographs was evidenced after two years of follow-up, the patient was asymptomatic and with full functional recovery.

Conclusion: The proposed technique appears to be reproducible, effective and easy to perform. Unlike the technique described by Blatt, the aim of this one is to restore the physiological position of the lunate bone by adding a second capsulodesis, as it is believed to be an essential factor in the maintenance of carpal kinematics.

Resumen

Introducción. La lesión del ligamento escafolunar (SLL, por su sigla en inglés) puede causar dolor e inestabilidad en la muñeca. Existe una amplia variedad de técnicas quirúrgicas utilizadas para el tratamiento de esta lesión, tales como capsulodesis dorsal, tenodesis con tendones flexores o extensores, e injerto hueso-ligamento-hueso.

Objetivo. Describir una nueva técnica para el tratamiento de la lesión del SLL, la cual busca estabilizar el carpo disociado con una doble capsulodesis dorsal.

Materiales y métodos. Mediante la presentación del caso de un hombre de 36 años que se desempeñaba como oficial de seguridad y se lesionó la muñeca izquierda en un accidente de motocicleta, se propone un procedimiento para alinear el carpo. Así mismo, se describe el resultado a largo plazo de este procedimiento.

Resultados. La cirugía propuesta se realizó con éxito; tuvo excelentes resultados clínicos y funcionales, y no presentó complicaciones. A largo plazo se evidenció la restauración de la alineación del carpo observada en las radiografías de muñeca tras dos años de seguimiento, el paciente se encontró asintomático y con recuperación funcional total.

Conclusiones. La técnica propuesta parece ser reproducible, eficaz y fácil de realizar. A diferencia de la técnica descrita por Blatt, el objetivo de esta es restaurar la posición fisiológica del hueso semilunar mediante la adición de una segunda capsulodesis, ya que se cree que es un factor esencial en el mantenimiento de la cinemática del carpo.

Palabras clave: Muñeca, Traumatismos de la Muñeca, Huesos del carpo.

Introduction

The treatment of chronic scapholunate ligament (SLL) injury aims to stabilize the carpus, both with muscle strengthening and with reconstructive surgical techniques that aim to restore the alignment and kinematics of the carpus, maintaining joint reduction during daily activities.

In 1987, Blatt¹ proposed the advancement of a dorsal capsule flap with a dorsoradial base with insertion at the distal pole of the scaphoid, with the aim of avoiding flexion deformity of the scaphoid. Some modifications were made to this technique, inverting the base and direction of the flap.^{2,3} Later, Slater & Szabo⁴ described the advancement of a segment of the capsule and dorsal ligaments of the carpus, joining the triquetrum and the distal pole of the scaphoid. Schweizer & Steiger⁵ used the technique of stabilizing the proximal pole of the scaphoid to the dorsum of the lunate. Wash *et al.*⁶ indicated joining the dorsal pole of the lunate to the triquetrum pole. Additionally, Brunelli & Brunelli⁷ and Van Den Abbeele *et al.*⁸ developed techniques to stabilize the carpus with a tendon graft, the so-called tenodesis. Garcia-Elias *et al.*⁹ refined the technique through a procedure known as three-ligament tenodesis, in which the authors performed the reconstruction of three carpal stabilizing ligaments, the scaphotrapezotrapezoid (STT), dorsal scapholunate and lunotriquetral ligament preventing the displacement of the scaphoid in flexion and pronation, and lunate bone shifting in extension and ulnar translation.

Our goal is to describe an innovative technique using two dorsal capsule-ligament flaps, elevated with opposite bases (proximal and distal) and advanced in the opposite direction, providing carpal bone stabilization targeting symptom improvement and preventing early joint degeneration.

Materials and methods

We propose a surgical procedure to restore the of carpal alignment seen in a 36-year-old man, a security officer, who injured his left wrist in a motorcycle accident. Additionally, we describe the long-term outcome of a patient, who underwent this new surgical procedure, who demonstrated excellent clinical and functional outcomes, with no reports of complications.

Technique description

The procedure is performed with brachial plexus block anesthesia and sedation, with the patient positioned in supine position and using a pneumatic tourniquet. The procedure should be performed with the assistance of an intraoperative fluoroscopy.

Initially, a six centimeters long longitudinal “S” shape surgical incision is made on the dorsoradial side of the wrist. The soft tissue dissection must be performed carefully to avoid iatrogenic injury of the cutaneous sensory branches of the radial nerve and the superficial venous system. After entering in the dorsal aspect of the joint, a 1 centimeter thick strip of the extensor retinaculum should be elevated, together with the tendons of the second to fifth dorsal extensor compartments, moving the extensor carpi radialis longus and brevis and extensor pollicis longus tendons to the radial side, and the remaining extensor tendons to the ulnar side. This maneuver provides a good view of the dorsal surface of the radius and the dorsal joint capsule.

Next, the flaps to be elevated were marked with a surgical pen in the dorsal capsule of the wrist. A radial flap was created with a proximal base, as described by Blatt¹, and an additional ulnar flap was formed with a distal base. The flaps were 1.3cm wide at the base and provide a wide view of the carpus and the injury (Figure 1).

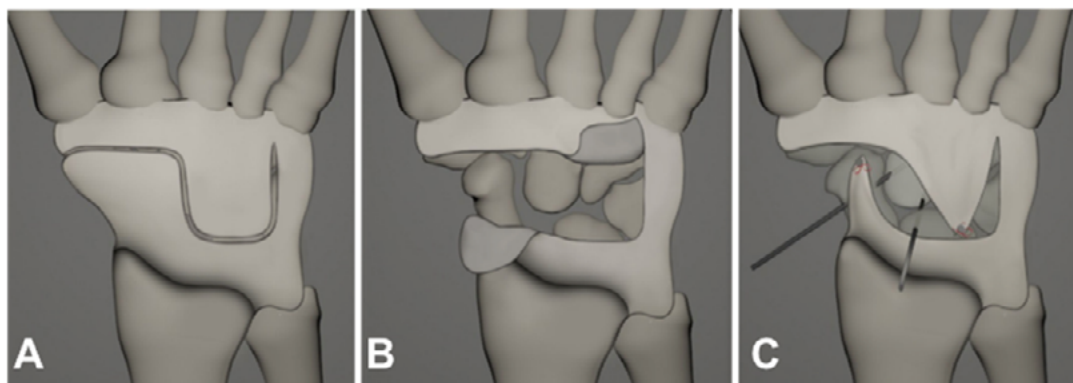


Figure 1. Double dorsal capsulodesis technique illustration. Initially, the flaps to be elevated were marked with a surgical pen in the dorsal capsule of the wrist. (A). One radial flap with a proximal base and another ulnar flap with a distal base are created (B). With the carpus aligned and reduced, a 2.5mm bone anchor is inserted in the dorsal and distal region of the scaphoid and another on the dorsum of the lunate bone. The radial capsular flap is anchored to the scaphoid and the ulnar flap is anchored to the lunate bone (C). Source: Own elaboration.

To facilitate restoration of joint alignment, 1.5mm Kirschner wires (K wires) should be inserted into the dorsum of both the scaphoid and lunate bones. Following the correction of scaphoid hyperflexion and lunate hyperextension, new K wires were used to temporarily fix the scaphoid and lunate bones in the second row of the carpus.

With the carpus aligned and reduced, a 2.5mm bone anchor is inserted in the dorsal and distal region of the scaphoid and another on the dorsum of the lunate bone. The proximally based radial capsular flap is then advanced and tensioned distally, being fixed to the scaphoid with the wrist slightly extended. Then, the distally based

ulnar flap is advanced proximally and fixed into the lunate. Both flaps were sutured individually through the bone anchors, and the union between them is not performed.

During the radial flap creation care must be taken to avoid iatrogenic injury to the radial artery branch, which passes close to the scaphoid. The same precaution must be taken in the ulnar flap with the dorsal radiotriquetral ligament.

At the end of the procedure, the retinaculum and skin are sutured and the wrist is immobilized with an antebrachio palmar splint. Weekly dressings are performed and the wrist must be immobilized for 6 to 8 weeks; in the meantime fingers and elbow active motion is encouraged. K wires, which are kept with their tips out of the skin, are removed at 8 weeks postoperative, and the patient is referred to a hand therapist. Thereafter, clinical and radiological evaluation is performed every three months, until reaching 12 months postoperative. The return to professional and sport activities is allowed 4 months after surgery.

Case description

The patient was a 36-year-old man, a security officer, who injured his left wrist in a motorcycle accident. After the trauma, he reported wrist pain, swelling and significant limitation of wrist mobility in the following 10 days, when he sought medical care where wrist and forearm radiographs were taken and interpreted as normal. He was given a provisional diagnosis of a “wrist sprain” (ICD 10 Diagnosis Code S63.8X2) and was immobilized with a removable forearm-palmar splint for 2 weeks. Fifteen days after the injury, the patient was still unable to move his wrist properly and the wrist pain was still present. Since no improvement was seen with the initial treatment, the exams were repeated and showed a 4 mm gap in the scapholunate space, with no evidence of dorsal intercalated segment instability (DISI).

Initially he was treated conservatively, with a wrist splint and oral nonsteroidal anti-inflammatory drugs as needed. At four months of follow-up, physical examination revealed exquisite tenderness over the scapholunate interval and a positive Watson’s test. Both findings

increased the suspicion of SLL injury, with Watson’s test having a positive likelihood ratio of 4.73.¹⁰ when used for diagnosing SLL injury. Wrist active range of motion was also limited in all directions due to pain and the patient demonstrated an important loss of grip strength (Table 1).

Table 1. Baseline clinical characteristics (preoperative)

Limb	LUE	RUE
Grip Strength	18 Kgf	39.50 Kgf
Wrist Flexion	45°	90°
Wrist Extension	40°	70°
Wrist Ulnar Deviation	15°	40°
Wrist Radial Deviation	11°	20°
Visual Analogue Scale	9	0
LUE=left upper extremity	RUE=right upper extremity	Kgf=kilogram-force

Source: Own elaboration

Individuals with an appropriate history and a Watson’s test should be considered as having a suspected SLL injury and should be evaluated further with appropriate imaging or arthroscopy.¹¹ Therefore, plain radiographs and magnetic resonance imaging (MRI) were ordered. Upon examination of the radiographs, it was noted that the scapholunate diastasis remained above physiologic values and a rotary subluxation of the scaphoid was evident. Corroboratively, the MRI demonstrated a complete tear of the scapholunate ligament, with rotational instability of the scaphoid and lunate bones (Figure 2).

At that point, surgical intervention was recommended using the reconstructive procedure with double dorsal capsulodesis, as described above (Figure 3).

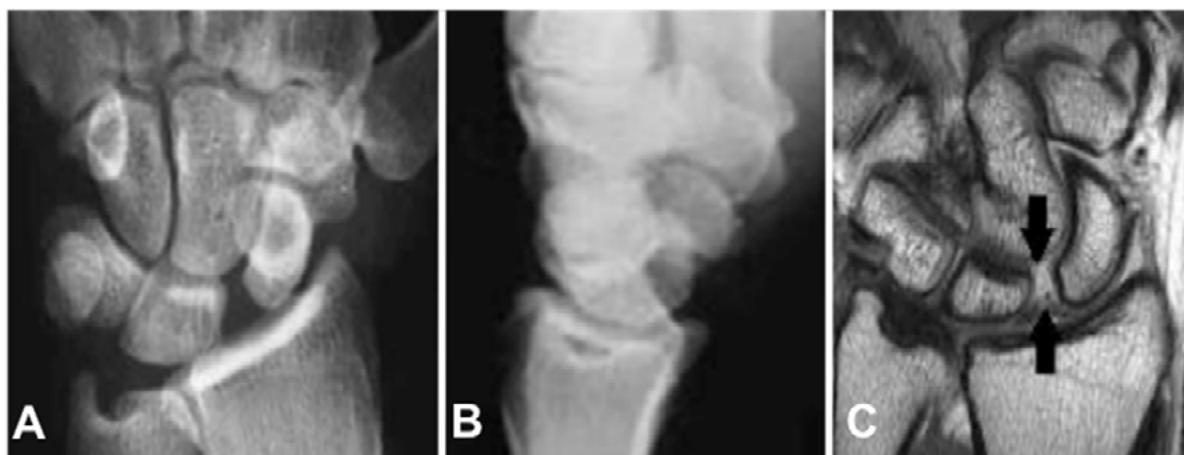

Figure 2. Radiographs from a 36-year-old male patient who suffered a wrist trauma with 4 months of follow-up, demonstrating an increased scapholunate interval and a DISI deformity (A and B). Magnetic resonance imaging showing a complete tear of scapholunate interosseous ligament (C).

Source: Own elaboration

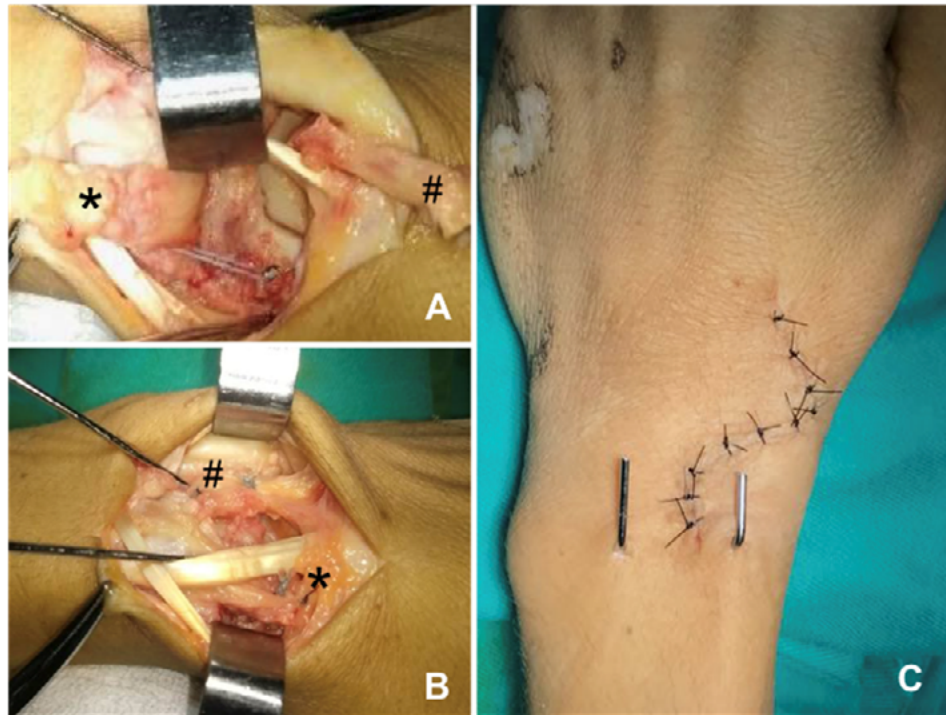


Figure 3. Surgical treatment was performed using the double dorsal capsulodesis technique. Initially, the radial capsular (*) and ulnar (#) flaps are elevated. Bone anchors were placed on the dorsum of the distal scaphoid and on the dorsum of the lunate bone (A). After carpal reduction, the flaps are sutured (B). Surgical incision immediately after the procedure completion (C). Source: Own elaboration

The surgical procedure proposed was performed successfully as evidenced by the restoration of carpal alignment seen on intraoperative wrist radiographs (Figure 4). After two years of follow-up, the patient was asymptomatic, with full functional recovery. Comparative data between the preoperative and postoperative periods are shown in (Table 2).

Table 2. Primary outcomes at 1 year follow-up.

Limb	LUE PREOP	LUE POSTOP	RUE
Grip Strength	18 Kgf	29 Kgf	39.50 Kgf
Wrist Flexion	45°	70°	90°
Wrist Extension	40°	50°	70°
Wrist Ulnar Deviation	15°	29°	40°
Wrist Radial Deviation	11°	14°	20°
Visual Analogue Scale	9	0	0
LUE=left upper extremity	RUE=right upper extremity	Preop= Preoperative Postop= Postoperative	Kfg=kilogram-force

Source: Own elaboration

Plain radiographs from this period also showed the maintenance of carpal alignment (Figure 4).

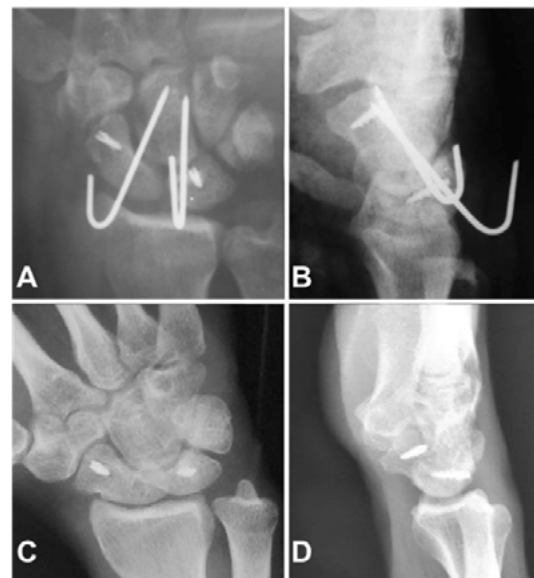

Figure 4. Immediate postoperative radiographs show restoration of carpal alignment (A and B). 24-months follow-up the imaging exams still demonstrate the maintenance of reduction (C and D). Source: Own elaboration.

Discussion

SLL injury is a frequent cause of wrist instability. Its initial diagnosis can be difficult and depends on the high degree of suspicion. The injury is considered acute if it has occurred within 6 weeks of presentation, at that point the ligament is still viable and amenable to suture or to receive direct bone reinsertion. Once an acute stage is over, reconstruction procedures, such as dorsal capsulodeses, tenodeses with flexor or extensor tendons, and scapholunate ligament reconstruction using a bone-retinaculum-bone autograft are indicated.

In the treatment of chronic SLL injury, one of the most widespread techniques is dorsal advancement capsuloplasty described by Blattl. It aims to limit the flexion-pronation movement of the scaphoid, preventing its static deformity. It is currently indicated for patients with pre-dynamic or dynamic dissociation and low functional demand, as it is associated with a 58% decrease in grip strength and a 49% decrease in wrist flexion.¹² The Blatt procedure can also cause radiological changes such as an increase in the scapholunate interval (SLI) and scapholunate angle (SLA), which is not always directly related to some functional disability.

Another similar technique, described by Mergele *et al.*,¹³ uses the same biomechanical principle of Blatt, however in this technique the authors use the dorsal intercarpal ligament to provide static stabilization between the triquetrum and the distal pole of the scaphoid. The advantage of this technique is to block the radiocarpal joint, reducing the risk of loss of wrist flexion. A study with 40 patients treated with this technique showed that 78% of the patients had wrist degenerative arthritis and a SLA enlargement with an average of 90° in an eight-year follow-up, although they maintained function.¹³

The three-ligament tenodesis procedure proposed by Garcia-Elias *et al.*,⁹ aims to stabilize the carpus by reconstructing three ligaments that stabilize the proximal row of the carpus; the STT, dorsal scapholunate and lunotriquetral ligament. Data from this 9-year-follow-up study showed 30% of poor outcomes due to associated wrist pain, limitation of range of motion and reduction of grip strength. In this group, it was also observed that the radiolunate angle (RLA) was 22° on average, the SLI was 4.6 mm and the SLA was 80°. Patients classified as good and excellent had a mean of 13° of RLA, 3.2 mm of SLI and 69° of SLA. And even those patients considered to have satisfactory results progressed to carpal degeneration, but without correlation with function and radiological examination.¹⁴ We believe that the procedure described in this study is less invasive than the proposed three-ligament tenodesis since it neither requires a volar approach to the wrist, nor a tendon dissection nor the need to perform bone tunnels.

The concave architecture of the distal radius along with the convex scapholunate joint creates a congruence and promotes joint harmony that is dependent on antagonistic forces that tend to keep the radial segment of the first row of the wrist in flexion and the ulnar segment of the wrist in extension. The new capsulodesis model proposed in this study has three main advantages: 1. being less invasive, minimizing the damage caused by techniques that require ample exposure of the wrist; 2. requires a single dorsal approach and; 3. avoids possible complications resulting from the construction of bone tunnels, such as the risk of avascular bone necrosis and fracture.

The results obtained by the different SLL reconstruction techniques are variable. The 2-year follow-up patient shown here, demonstrated an excellent outcome, presenting clinical and radiological parameters

very similar to those of the opposite wrist. Clinically, the patient demonstrated a recovery of 73% of grip strength, 77% of flexion and 72% of radial deviation compared to the contralateral side. Similar to the results obtained in patients undergoing three-ligament tenodesis, which have a mean RLA of 13°, SLI of 3.2 mm and SLA of 69°, and according to their classification such outcomes were considered good.¹⁴ On the other hand, isolated Blatt capsulodesis limits grip strength by 58% and flexion by 49%, when compared to the opposite side.¹²

The proposed technique aims to stabilize the forces that tend to generate the flexion deformity of the scaphoid using the procedure proposed by Blatt with the addition of the contention of lunate bone using a second, more ulnar flap of the dorsal capsule based on the capitate. Thus, during wrist flexion, the tension of the radial capsulodesis, which crosses the radiocarpal joint, keeps the scaphoid extended while the lunate remains in flexion due to the tension that is created by the ulnar capsulodesis. In extension, the forces that tend to increase the lunate deformity in extension are stabilized by the ulnar flap, maintaining the carpal alignment. Therefore, this technique aims to give greater importance to the stabilization of the lunate bone as a crucial factor in the maintenance of carpal kinematics. Furthermore, the procedure proved to be an easy and effective technique, with satisfactory clinical and radiological outcomes.

The procedure described in this study is contraindicated in cases of non-reducible static instabilities and those affected by a degenerative process, such as a scapholunate advanced collapse (SLAC). Potential complications are the same as for other similar procedures performed on the wrist, such as infection, stiffness, mainly due to loss of wrist flexion, and complex regional pain syndrome. In order to avoid mechanical complications, it is important that both flaps have the same tension. And this can be achieved by keeping the wrist slightly at 30 degrees of extension during the flaps suturing, gaining greater stiffness when the wrist returns to the neutral position, since the radial flap is tensioned by crossing the radiocarpal joint and the ulnar flap by crossing the midcarpal joint. We emphasize the benefit of performing the stabilization of the lunate in flexion using a capitate-based dorsal capsule flap, simultaneously with the correction of the scaphoid positioning.

Conflicts of interest

None stated by the authors.

Funding

None stated by the authors.

Acknowledgements

None stated by the authors.

References

1. Blatt G. Capsulodesis in reconstructive hand surgery. Dorsal capsulodesis for the unstable scaphoid and volar capsulodesis following excision of the distal ulna. *Hand Clin.* 1987;3(1):81-102.
2. Herbert TJ, Hargreaves IC, Clarke AM. A new surgical technique for treating rotary instability of the scaphoid. *Hand Surg.* 1996;1(1):75-7. DOI: 10.1142/S0218810496000130.

3. Linscheid RL, Dobyns JH. Treatment of scapholunate dissociation. Rotatory subluxation of the scaphoid. *Hand Clin.* 1992;8(4):645-52.
4. Slater RR Jr, Szabo RM. Scapholunate dissociation: treatment with the dorsal intercarpal ligament capsulodesis. *Tech Hand Upper ExtremSurg.* 1999;3(4):222-8.
5. Schweizer A, Steiger R. Long-term results after repair and augmentation ligamentoplasty of rotatory subluxation of the scaphoid. *J Hand Surg.* 2002;27(4):674-84. DOI: 10.1053/jhsu.2002.34320.
6. Walsh JJ, Berger RA, Cooney WP. Current status of scapholunate interosseous ligament injuries. *J Am Acad Orthop Surg.* 2002;10(1):32-42. DOI: 10.5435/00124635-200201000-00006.
7. Burnelli GA, Brunelli GR. A new technique to correct carpal instability with scaphoid rotary subluxation: a preliminary report. *J Hand Surg Am.* 1995;20(3 Pt 2):S82-5. DOI: 10.1016/s0363-5023(95)80175-8.
8. Van Den Abeele KL, Loh YC, Stanley JK, Stanley JK, Trail IA. Early results of a modified Brunelli procedure for scapholunate instability. *J Hand Surg Br.* 1998;23(2):258-61. DOI: 10.1016/s0266-7681(98)80191-5.
9. Garcia-Elias M, Lluch AL, Stanley JK. Three-ligament tenodesis for the treatment of scapholunate dissociation: indications and surgical technique. *J Hand Surg Am.* 2006;31(1):125-34. DOI: 10.1016/j.jhsa.2005.10.011.
10. Valdes K, LaStayo P. The value of provocative tests for the wrist and elbow: a literature review. *J Hand Ther.* 2013;26(1):32-42. DOI: 10.1016/j.jht.2012.08.005.
11. Kitay A, Wolfe SW. Scapholunate instability: current concepts in diagnosis and management. *J Hand Surg Am.* 2012;37(10):2175-96. DOI: 10.1016/j.jhsa.2012.07.035.
12. Misra A, Hales P. Blatt's capsulodesis for chronic scapholunate instability. *Acta Orthop Belg.* 2003;69(3):233-8.
13. Megerle K, Bertel D, Germann G, Lehnhardt M, Hellmich S. Long-term results of dorsal intercarpal ligament capsulodesis for the treatment of chronic scapholunate instability. *J Bone Joint Surg Br.* 2012;94(12):1660-5. DOI: 10.1302/0301-620X.94B12.30007.
14. Geominn S, Borgers A, van Beek N, de Smet L, Degreef I. Long-term follow-up of the three-ligament tenodesis for scapholunate ligament lesions: 9-year results. *Hand Surg Rehabil.* 2021;40(4):448-52. DOI: 10.1016/j.hansur.2021.03.020.